

CASE STUDY: Animated presentation software as an essential educational tool for patient treatment understanding and increased revenues.

ABSTRACT

A 45 year old male presented with a missing lower incisor and obvious severe tooth wear. This scenario often results in a typical remedial solution of replacing the lower missing tooth with an implant /crown or a fixed bridge. Visual presentation using BiteFX animations combined with a complete examination enhanced the patient's understanding. The resultant comprehensive treatment plan greatly benefited the patient, enhanced the practice's image in the community and profoundly affected productivity.

PATIENT HISTORY – Grinding loosens tooth, falls out, but periodontally sound mouth.

The patient was aware of tooth grinding while working in his cabinet shop and knew his lower tooth had become increasingly mobile over time. A very mild trauma to the lower teeth loosened the tooth so that he removed it himself with little effort (Fig. 1). His mouth was periodontally sound, had no caries and only several posterior gold crowns which he stated were placed after his molars fractured. The patient came to my office ostensibly to have a limited treatment to reconstruct the missing tooth.

PATIENT CONSULTATION WITH BiteFX – Easy to gain patient acceptance of full exam.

After a brief visual inspection and prior to the examination, several animations from BiteFX were used to give the patient insights on the type of examination that would be performed, including lack of anterior guidance and what normal canine guidance should look like (Fig. 2 & 3). I also discussed how occlusal disease is unfortunately ignored by many practitioners. Knowing this patient, like most others, had never experienced a complete occlusal exam, I used the BiteFX animations and photo gallery to make the exam findings relevant. BiteFX also demonstrated to the patient our practice commitment to diagnosing all forms of dental disease.

Before beginning the exam, the patient quickly became aware of the true extent of his problem, and asked how to solve it. As a result, it was easy to gain patient acceptance of expanding the exam to include obtaining bite records, face bow transfers, intraoral photography and mounted study models.

TREATMENT – Restoration, veneers, implant, crown, extending to restoring posteriors.

The patient's chief complaint was the missing lower incisor. He understood the need to restore his upper teeth to create anterior guidance. Initial equilibration was performed to allow CR to coincide with his acquired bite (MIP). The following bullet points highlight the course of treatment:

- A composite mock up was performed chairside to restore his upper anterior teeth to their original unworn shape and size (Fig. 4).
- The mock up was used for the provisional matrix impression, and the teeth were prepared for veneers. Final impressions, bite records and shade selection were created. Final restorations were feldspathic porcelain.
- A Biohorizons™ 3.5 x 12 mm internal implant was placed at time of final impression at the end of the restorative appointment.
- After implant integration, the client opted to restore his implant crown and additional seven lower anterior teeth to color harmonize with the uppers. Conservative minimal prep feldspathic veneers were used, and an all-ceramic crown was used on the implant.
- Ultimately the client chose to restore his remaining posterior teeth to complete the color changes to all teeth, and obtain anatomically shaped teeth as his natural teeth were ground flat (Fig. 5).

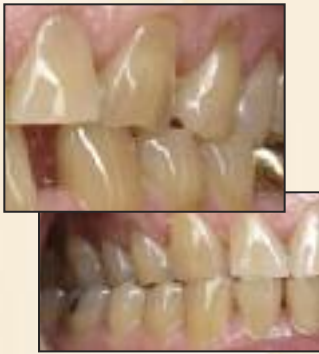

Fig. 1 Lateral view of patient with missing tooth and evidence of unusual wear, with contralateral view showing excessive wear due to poor anterior guidance.

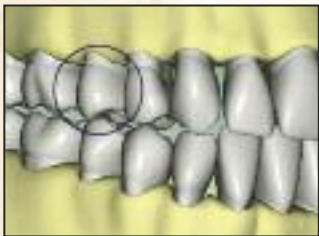


Fig.2 BiteFX animation used to demonstrate effects of poor anterior guidance on teeth.

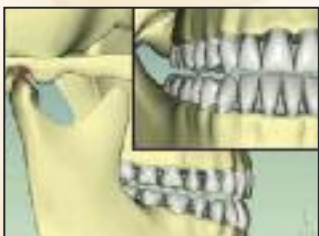

Fig. 3 BiteFX animation with side-by-side animation to explain normal anterior guidance.

RESULTS – BiteFX helped extend treatment plan from single tooth to full mouth.

The patient granted permission to meet on another day in order to properly evaluate the findings, present a diagnosis and make the required treatment recommendations. Because the patient was able to clearly understand his dental problem with the aid of BiteFX animations, the treatment plan was extended well beyond a simple replacement as described in the Treatment section above. The client was extremely pleased with his results.

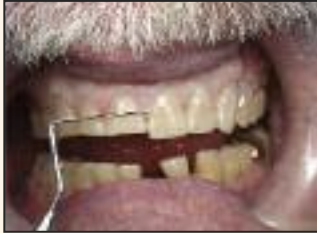

Fig. 4 Partial restoration of upper anterior teeth using composite material.

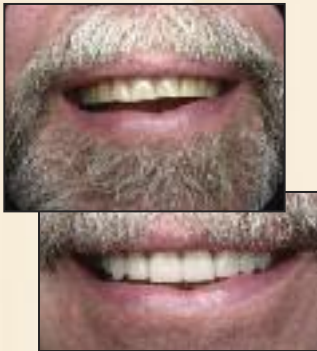

Fig. 5 Comparison of patient's pre-treatment tooth wear and final result after upper anterior restoration.

DISCUSSION – Financial and qualitative impact of BiteFX.

- Before acquisition of the BiteFX product, presentation of occlusal problems were difficult and patient understanding frequently poor.
- BiteFX allowed me to convey clearly and convincingly to this patient the cause of his problems, resulting in a \$35K comprehensive treatment plan as compared to a \$3500 plan that might otherwise have been requested to solely address the primary complaint.
- The presentation software is very simple and easy to present for me and my staff.
- The design of BiteFX allows me to automatically or manually control animation sequences.
- The ability to add individual patient images and present them with the animations enhances my consultations and has greatly increased my case acceptance rate.

*Developed by Dynamic Thought® and Don Reid DDS, the BiteFX™ animation software provides the dental professional with a simple to use, easy to present graphic tool for presentation of malocclusion concepts to the dental patient. BiteFX is compatible with Windows operating systems.**

"When I read a previous testimonial that BiteFX paid for itself on the first case presentation, I thought it would be worth a try. On my second time using it for a case presentation, it did pay for itself... 35 times over!"

-Robert R. Cowie, DDS Jacksonville, Florida

"Thanks for the BiteFX software. It is absolute magic and just what I have been wishing for, for the past 20 years! Brilliant, thanks for making my life easier and helping patients too!"

-Charley Varipapa, DDS Alexandria, Virginia

"There isn't a day that goes by that I am not thankful for the use of the Bite FX to show my patients. It is so helpful."

-TJ Bolt, DDS Omaha, Nebraska

For additional information or customer support, please contact BiteFX at 1.877.224.8339 or 1.530.582.1189.

BiteFX™

11445 Cinder Cone Court, Truckee, California 96161
t: 1.877.2BiteFX (1.877.224.8339), f: 1.530.579.3237
e: info@bitefx.com, w: bitefx.com

* Special arrangements can be made for those wishing to use the animations on Macintosh systems.

© 2010 D2Effects, LLC. BiteFX™ and the BiteFX™ logo are trademarks of D2Effects, LLC. All rights reserved.